

SEAN I. DOCKING, BHSc (Hons)^{1,2} • CHIN CHIN OOI, MMedUS, BAppSc^{3,5}
DAVID CONNELL, MBBS, MMed^{4,5}

Tendinopathy: Is Imaging Telling Us the Entire Story?

The old saying goes, “A picture is worth a thousand words.” The imaging of tendons with ultrasound and magnetic resonance imaging (MRI) has been utilized in the clinical setting to assist in the diagnosis of tendinopathy, monitor the efficacy of treatments, and assess the risk of developing symptoms.^{44,73,81} However, while imaging shows the presence and extent of structural changes within the tendon,

the clinical interpretation of the images requires context in regard to the features of pain (location and distribution) and the aggravating factors (loading related to increases in pain). This is due to the

limited relationship between structural disorganization and pain, similar to other musculoskeletal conditions such as osteoarthritis and intervertebral disc degeneration.⁸¹ Clinically, tendon abnormalities



on imaging do not confirm that pain and dysfunction are generated by the tendon.⁷⁷ Conversely, a relatively normal tendon does not rule out the tendon as the source of pain and dysfunction. In the case of tendons, we may need to make an addition to the old saying that a picture is worth a thousand words—but only as an adjunct to the clinical picture.” This clinical commentary discusses the imaging features of the pathological tendon, accuracy and sensitivity of ultrasound and MRI, novel imaging modalities, the role of imaging in the clinical and research settings (prediction of symptoms and monitoring), and future directions.

Tendinopathy is the clinical condition that describes pain and dysfunction of the tendon, which is independent of pathology within the tendon.⁵³ It is frequently described as localized pain that increases with greater load (ie, single-leg hopping is more painful for the Achilles tendon than calf raises).^{15,77} Degenerative changes in structure observed histologically or on imaging, independent of clinical symptoms, are termed *tendinosis*.^{53,72} These terms have been used interchangeably in the literature; however, it is important to clarify that they represent differing aspects of the same condition and highlight the disconnect between structure and pain.

● **SYNOPSIS:** Tendinopathy is frequently associated with structural disorganization within the tendon. As such, the clinical use of ultrasound and magnetic resonance imaging for tendinopathy has been the focus of numerous academic studies and clinical discussions. However, similar to other musculoskeletal conditions (osteoarthritis and intervertebral disc degeneration), there is no direct link between tendon structural disorganization and clinical symptoms, with findings on imaging potentially creating a confusing clinical picture. While imaging shows the presence and extent of structural changes within the tendon, the clinical interpretation of the images requires context in regard to the features of pain and the aggravating loads. This review will critically evaluate studies that have investigated the accuracy and sensitivity of imaging in the detection of clinical tendinopathy and the methodological issues associated with these studies (subject selection, lack of a robust gold standard, reliance

on subjective measures). The advent of new imaging modalities allowing for the quantification of tendon structure or mechanical properties has allowed new critical insight into tendon pathology. A strength of these novel modalities is the ability to quantify properties of the tendon. Research utilizing ultrasound tissue characterization and sonoelastography will be discussed. This narrative review will also attempt to synthesize current research on whether imaging can predict the onset of pain or clinical outcome, the role of monitoring tendon structure during rehabilitation (ie, does tendon structure need to improve to get a positive clinical outcome?), and future directions for research, and to propose the clinical role of imaging in tendinopathy. *J Orthop Sports Phys Ther* 2015;45(11):842-852. Epub 21 Sep 2015. doi:10.2519/jospt.2015.5880

● **KEY WORDS:** magnetic resonance imaging, tendinosis, tendon, ultrasound

¹Monash Tendon Research Group, Monash University, Clayton, Australia. ²Australian Centre for Research Into Injury in Sport and Its Prevention, Federation University Australia, Ballarat, Australia. ³Department of Diagnostic Radiology, Singapore General Hospital, Singapore. ⁴Department of Medical Imaging and Radiation Sciences, Monash University, Clayton, Australia. ⁵Imaging @ Olympic Park, Melbourne, Australia. Mr Docking received funding from an ultrasound tissue characterization imaging company to attend a conference in April 2013, and is supported by the Australian Centre for Research Into Injury in Sport and Its Prevention, which is one of the International Research Centres for Prevention of Injury and Protection of Athlete Health supported by the International Olympic Committee. Mr Docking was supported by the Monash University Postgraduate Publication Award for the preparation of this paper. The authors certify that they have no other affiliations with or financial involvement in any organization or entity with a direct financial interest in the subject matter or materials discussed in the article. Address correspondence to Mr Sean Docking, PO Box 527, Frankston, Victoria 3199 Australia. E-mail: s.docking@latrobe.edu.au © Copyright ©2015 *Journal of Orthopaedic & Sports Physical Therapy*®

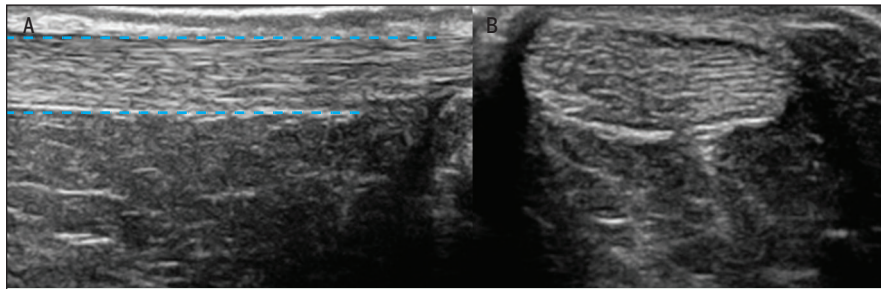


FIGURE 1. Ultrasound of a healthy Achilles tendon. (A) Longitudinal and (B) transverse ultrasound images of the mid Achilles tendon. The normal tendon texture appears homogeneous, with parallel echogenic lines reflecting the internal fibrillar structure of the tendon. The dashed blue lines represent the superficial and deep borders of the tendon.

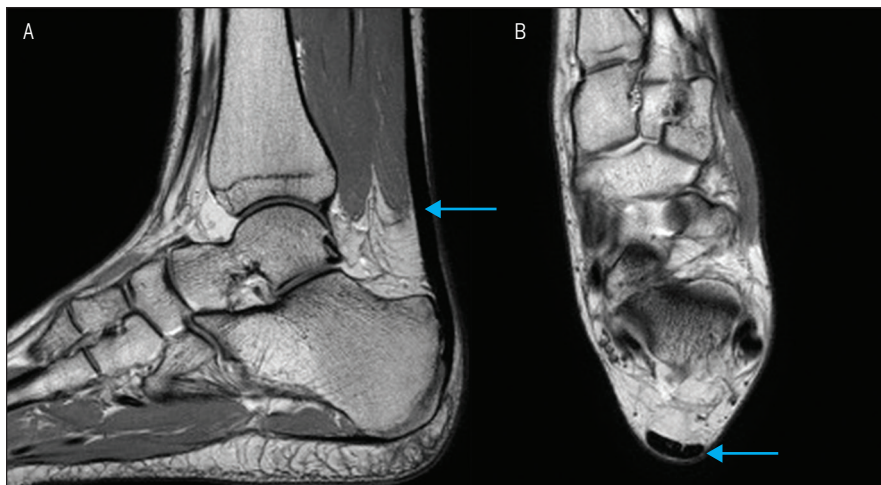


FIGURE 2. Magnetic resonance imaging of a normal Achilles tendon. (A) Sagittal and (B) axial proton density-weighted sequence image showing a normal Achilles tendon (arrow) with uniform thickness and predominantly low signal intensity.

Features of Normal and Pathological Tendons on Imaging

Imaging allows for the visualization of the internal architecture of the tendon. Normal tendon primarily contains type I collagen that is hierarchically arranged into parallel-aligned fibrils, fibers, and fascicles.^{31,64,76,80} This uniform alignment of fibers can be visualized in normal tendons using ultrasound imaging at the fascicle level (**FIGURE 1**). Water and non-collagenous proteins, such as proteoglycans, are present between the fibers and fascicles, which allow tendon lengthening through interfascicular sliding rather than fiber extension.^{82,92} This relationship between water and collagen results in a strong dipole interaction and little signal being observed on MRI in the normal tendon (**FIGURE 2**).^{9,99} Finally, normal ten-

dons are relatively avascular, especially when observed with Doppler ultrasound (**FIGURE 3**).⁶⁵

Four main histological changes are observed in tendinosis, the primary change being increases in cell numbers that exhibit an altered, more metabolically active phenotype.^{10,47} Rather than flattened tenocytes that are arranged parallel between fibers, increased numbers of rounded, activated tenocytes are interspersed throughout the pathological tendon.⁴⁷ While determining changes in cell number and phenotype are beyond the resolution of clinical imaging modalities, the consequence of these active metabolic cells can be detected. A shift in the proteoglycan content, from the small leucine-rich proteoglycans (eg, decorin) to the larger hydrophilic proteoglycans (eg,

aggrecan), results in an increase in bound water and tendon thickening.^{20,80} These changes have been described on ultrasound as increases in tendon dimensions and heterogeneous or diffuse changes in echogenicity,^{19,57} and ultrashort echo time MRI has shown alterations in the hydration state of the tendon.⁴⁰ Previous work in asymptomatic patellar tendons suggests that abnormal tenocyte morphology and changes in proteoglycan content are the primary changes in tendinosis.¹³

Fibrillar disorganization is another feature of tendinosis in which fibers are present in a haphazard arrangement, somewhat due to the change from type I collagen to type II and III collagen.⁵⁴ The parallel arrangement of normal tendon fibers generates a single ultrasound reflection when the ultrasound probe is perpendicular to the long axis of the tendon. Multiple reflections and shadowing are generated by fibrillar disorganization and lack of parallel-aligned fibers, which are represented by an area of hypoechogenicity on ultrasound (**FIGURE 4**).⁷³ On MRI, the alteration in fibrillar alignment and increased water content result in an increase in intratendinous signal (**FIGURE 5**).^{9,99}

Neovascularization within the pathological tendon can be imaged with color and power Doppler ultrasound imaging (**FIGURE 3**).^{6,33} Weinberg et al⁹⁸ reported that Doppler flow was only observed in tendons that contained an area of hypoechogenicity and not in abnormally thickened tendons with normal echogenicity. This association between the presence of blood vessels and areas of matrix disorganization suggests that the infiltration of blood vessels may be opportunistic.⁴³ The infiltration of blood vessels and accompanying nerves has previously been implicated as a source of pain, with moderate associations reported between Doppler signal and the presence and location of pain,^{22,27,38} with Doppler signal also being associated with poorer clinical outcomes.⁴⁹ However, increased Doppler signal is present in asymptomatic tendons, suggesting that

blood vessels and accompanying nerves are not the primary source of pain.^{18,38} It is also important to note that the reliability of detecting Doppler signal is poor,¹⁷ with exercise affecting the presence/absence of Doppler signal.¹⁶

The pathological features outlined above are not the only indication of pathology within the tendon. Partial tears, especially in the rotator cuff of the shoulder, are frequently described. However, there is no consensus on the features of partial tears, and a number of studies have reported difficulty in differentiating partial tears from tendinosis.^{68,75} Bony spurs and areas of calcification, frequently near the tendon's bony insertion, have previously been described as a "tombstone of tendon pathology," yet recent investigations have shown that they have little impact on the development of symptoms.¹² Extratendinous tissues, such as the paratendinous sheath, associated bursa, and fat pad, can also display changes on imaging yet have a different pathogenesis from that of tendinosis.⁷³

Paratendinitis is described as an inflammatory response of the tendon sheath, which clinically can present as crepitus and pain through range of movement. Thickening of the sheath and the presence of fluid surrounding the tendon are frequently observed on ultrasound (FIGURE 6), with adhesions of the sheath to the tendon occurring in chronic cases that can be observed on dynamic ultrasound.^{67,101} Imaging can be useful in the diagnosis of paratendinitis, as it can be present in conjunction with tendinosis and should be considered during rehabilitation (ie, reducing joint movement and friction between the sheath and tendon).

Accuracy, Sensitivity, and Validity of Imaging

There has been considerable debate on the clinical utility of imaging in tendinopathy. There have been numerous studies that have investigated the accuracy (number of correct imaging diagnoses, both abnormal and normal imaging, divided by the total number of cases) and

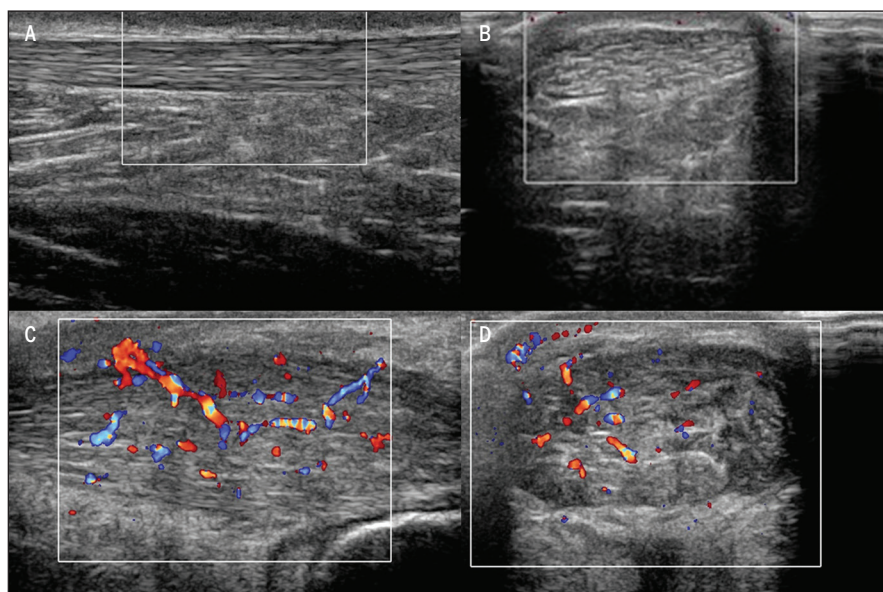


FIGURE 3. Ultrasound image of an Achilles tendon with color Doppler. (A) Longitudinal and (B) transverse images of a normal, asymptomatic Achilles tendon showing normal tendon echo texture with no Doppler signal. (C) Longitudinal and (D) transverse images of a symptomatic Achilles tendon showing significant thickening of the tendon and the presence of hypoechoic changes. Significant Doppler signal is also apparent within the tendon.

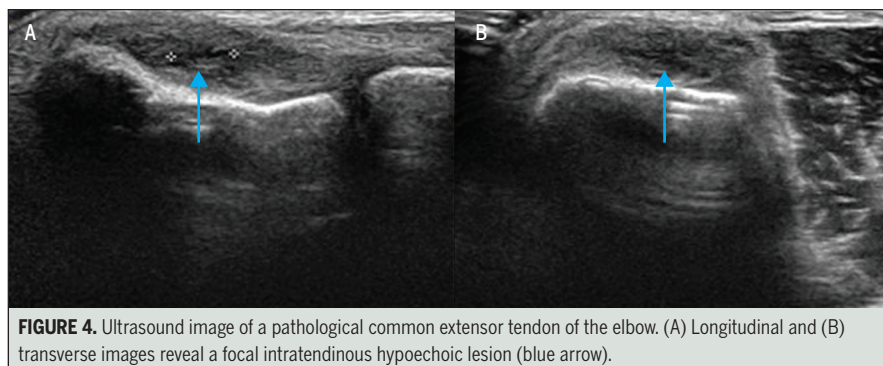


FIGURE 4. Ultrasound image of a pathological common extensor tendon of the elbow. (A) Longitudinal and (B) transverse images reveal a focal intratendinous hypoechoic lesion (blue arrow).

sensitivity (number of correct abnormal imaging diagnoses divided by the total number of symptomatic cases) of a number of imaging modalities in detecting clinical tendinopathy. A central issue with studies that test the accuracy of imaging is the lack of a valid clinical gold standard. The diagnosis of tendinopathy can be complex, due to a confusing clinical picture with few clinical diagnostic tests for tendinopathy. As yet, there is no consensus as to which clinical exam may serve as the gold standard for the diagnosis of tendinopathy, with pain on palpation, location of pain, and pain during certain movements frequently used as the reference tests when testing the accuracy

of imaging. However, the accuracy and sensitivity of these measures vary across studies.^{42,74} Determining the accuracy of imaging is dependent on how valid the gold standard is. With that yet to be ascertained, caution is advised when assessing the accuracy of imaging in detecting clinical tendinopathy.

A number of studies have investigated the accuracy of imaging in diagnosing tendinopathy. These studies have consistently shown that both ultrasound and MRI have good to excellent accuracy (ultrasound, 0.63-0.83; MRI, 0.68-0.70) but varying sensitivity (ultrasound, 0.68-0.87; MRI, 0.50-0.57) in detecting clinical tendinopathy.^{1,45,48,49,62,97} But caution

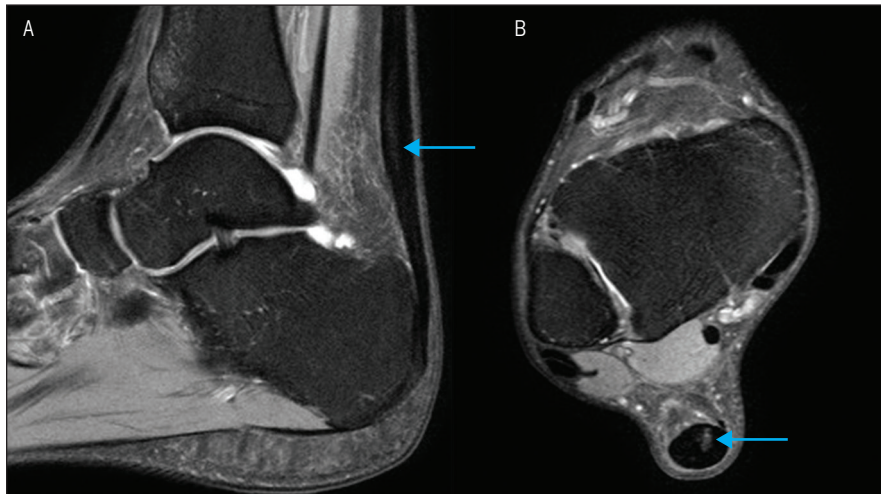


FIGURE 5. Magnetic resonance imaging of an abnormal Achilles tendon. (A) Longitudinal and (B) transverse images reveal increased signal intensity (blue arrow) within the mid substance of the tendon.

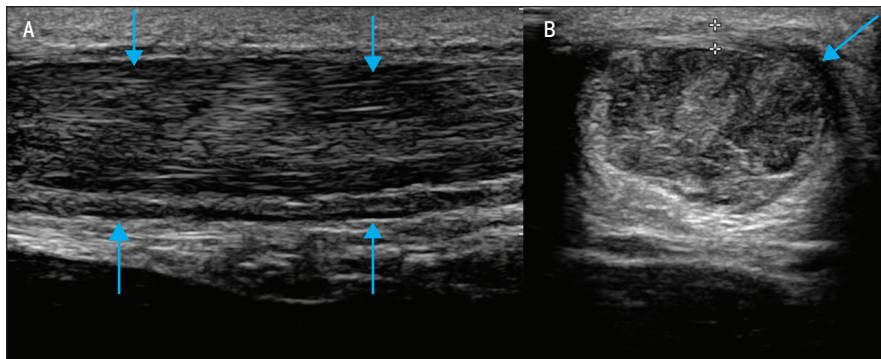


FIGURE 6. Paratenonitis. (A) Longitudinal and (B) transverse ultrasound images of the Achilles tendon showing thickened and edematous paratenon (arrows) surrounding the tendon, with a background of thickened, hypoechoic, and heterogeneous Achilles tendon.

is required when interpreting the results of these studies, as asymptomatic participants are frequently included, and their inclusion may result in an overestimation of the accuracy and sensitivity of imaging in detecting clinical tendinopathy. Participant selection in these studies is critical, and future studies need to reflect the use of imaging in the clinical setting (ie, imaging to differentiate tendinopathy from other pain conditions in the same anatomical region).

Due to ethical issues in collecting tissue from appropriate controls, most studies have compared imaging to a clinical diagnosis as the gold standard,⁴⁹ with few studies comparing findings on imaging to surgical or histological findings. A number of studies have reported

variable sensitivity values (0.33-1.00) but good to excellent accuracy (0.91-0.95) of imaging compared to surgical findings.^{46,61,88,96,100} For example, Adams et al¹ identified subscapularis tears on MRI in 16 patients that were confirmed by arthroscopy, yet 28 patients with subscapularis tears identified arthroscopically had normal MRI. Similar findings have been reported for the Achilles tendon, where ultrasound diagnosis correlated with surgical findings in approximately 80% of cases,^{3,68} with ultrasound imaging being limited in its ability to differentiate between partial Achilles rupture and local degenerative lesions.⁶⁸ Caution is advised when extrapolating the accuracy and sensitivity findings of these studies to the diagnosis of tendi-

nopathy, as the majority of studies investigated the ability to identify partial tears due to this condition frequently requiring surgery. Shalabi et al⁸⁵ found that intratendinous signal observed on dynamic contrast-enhanced MRI correlated with the severity of histopathological changes. Histopathological comparison to ultrasound has shown that areas of hypoechoicities contained significant tendon pathology, with areas adjacent subjectively described as “normoechoic” also exhibiting pathological changes, yet to a lesser extent.⁶¹

Which Imaging Modality Is the Gold Standard?

Radiographs and computed tomography scanning have been used to image tendons^{7,59,89}; however, ultrasound and MRI are the preferred imaging modalities. Magnetic resonance imaging has excellent soft tissue contrast detail and multiplanar imaging capabilities with excellent reproducibility.⁵ However, MRI is costly and of limited availability. Advances in ultrasound transducer technology and improvement in the sensitivity of Doppler imaging have increased the utility of ultrasound. However, it is somewhat user dependent, as slight changes in the ultrasound transducer tilt generate imaging artifacts that are similar to those seen with tendon pathology.⁷³ Ultrasound imaging can focus on an area of pain or clinical suspicion of pathology, whereas MRI provides a global assessment of the region of concern.

Few studies have directly compared MRI and ultrasound imaging. Westacott et al¹⁰⁰ performed a systematic review and reported that the sensitivity of MRI for detecting gluteal tendon tears ranged from 0.33 to 1.00, whereas specificity was consistently high (0.92-1.00). In contrast, ultrasound was found to be a highly sensitive technique (0.79-1.00), suggesting that ultrasound may be used as a first-line imaging modality for evaluating gluteal tendon tears. Similarly, previous investigations have reported that ultrasound demonstrates higher sensitivity

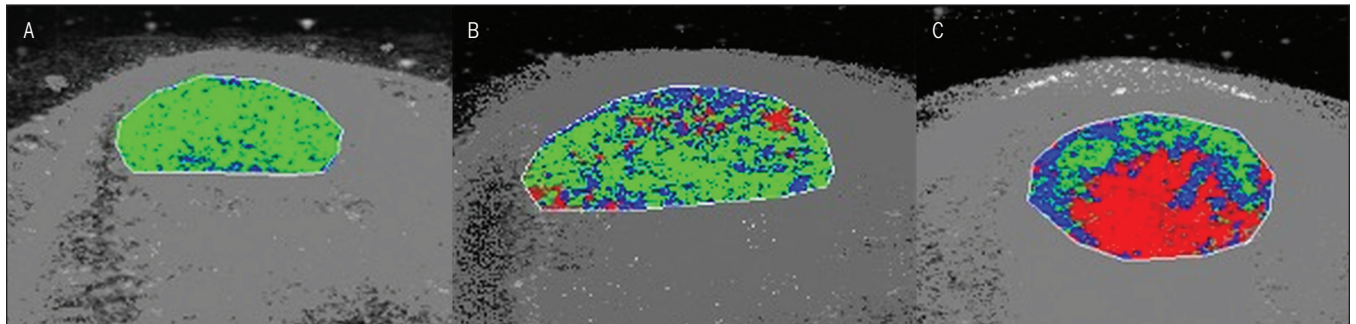


FIGURE 7. Ultrasound tissue characterization of the Achilles tendon mid substance. (A) Normal Achilles tendon characterized by a high proportion of echo type I (green pixels), representing aligned tendon bundles. (B) Reactive tendinopathy due to tendon thickening and the presence of diffuse speckling of echo type II (blue pixels) and echo type III (red pixels). (C) Degenerative tendinopathy indicated by significant focal area of echo type III (red pixels).

but lower specificity compared to MRI in detecting clinically symptomatic rotator cuff tendinopathy.⁹⁹ However, MRI has been reported to be superior in the evaluation of various degenerative changes in the Achilles tendon.^{61,63}

There is value in both MRI and ultrasound imaging, with the imaging modality to be used being based on patient presentation. Magnetic resonance imaging may be suitable where differential diagnosis is required (eg, visualization of patellofemoral joint chondral changes mimicking aspects of patellar tendon pain). However, due to the superior spatial resolution of ultrasound in the visualization of fibrillar alignment and vascularity,⁷³ ultrasound may better image the internal architecture of the tendon. The ability of ultrasound to provide a dynamic image during active and passive movements may provide further information, especially in differential diagnosis (eg, fat-pad or sheath adhesion to the tendon, sciatic nerve tethering to the proximal hamstring tendon).

New Imaging Modalities

Conventional imaging modalities are criticized for their reliance on subjective interpretation of images. Research has been limited to classifying the tendon as abnormal or normal, or to the use of a subjective grading score based on myriad pathological features and their severity. Objective quantification of tendon structure has been limited to measurements relating to tendon dimensions (antero-

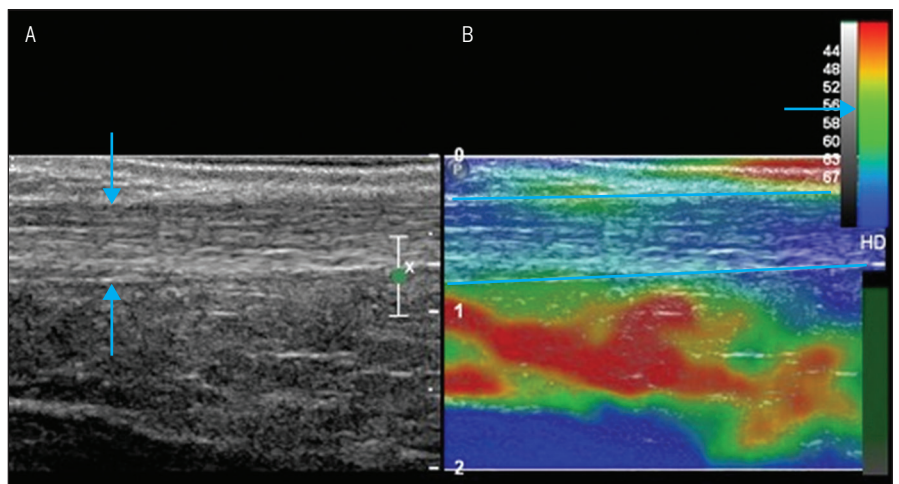


FIGURE 8. Dual-mode display of B-mode (A) ultrasound and (B) sonoelastogram of a 25-year-old man. The longitudinal B-mode ultrasound (A) displays the normal homogeneous, linear fibrillar echo pattern of the mid Achilles tendon (arrows). The corresponding sonoelastogram (B) shows blue-colored Achilles tendon (between lines) overlaid on the conventional B-mode image, which represents normal, stiff tendon structure. An elastography color map bar is shown on the right upper corner of the image (arrow). Abbreviation: B-mode, brightness mode.

posterior diameter or cross-sectional area) and the percentage of cross-sectional area of the hypoechoic lesion. Tendon research may be improved with new imaging techniques that address these limitations and begin to provide information on the mechanical properties of the tendon.

Ultrasound Tissue Characterization The aligned fibrillar structure of tendon results in a homogeneous echo texture on ultrasound imaging, where the stability in echo texture can be quantified.^{4,60} Ultrasound tissue characterization (UTC) captures contiguous transverse ultrasound images over the length of the tendon and semi-quantifies the stability of the echo

texture over the length of the tendon into 4 echo types (see van Schie et al⁹⁵ for further explanation of the 4 echo types). Research performed on equine histopathological samples found that UTC echo types were able to distinguish between different tissue types (normal, granulation, and fibrotic tissue), where basic grey level statistics could not.^{93,94} The ability to capture a 3-dimensional ultrasound image of the tendon, which standardizes parameters that affect the repeatability of conventional ultrasound (ie, transducer tilt angle, depth, and gain settings), and semi-quantification of tendon structure attempt to address the limitations of conventional ultrasound imaging.

While UTC echo types have not been compared to tendon biopsies in humans due to ethical considerations, the structure of equine and human tendons is similar.⁶⁹ van Schie et al⁹⁵ scanned a cross-section of individuals with and without Achilles tendon pain and reported that the percentage of intact and aligned tendon bundles (echo type I) was reduced in the symptomatic tendon, with increases in echo types that represent disorganized structure (echo types III and IV). The ability to semi-quantify the structural integrity of the tendon has allowed for classification of the tendon pathology based on a continuum (FIGURE 7), treatment efficacy to be investigated,^{21,23,24} detection of subtle changes in response to load,^{29,79} and demonstration that the asymptomatic Achilles tendon is structurally compromised in individuals with unilateral tendon pain.³⁰

Sonoelastography Ultrasound elastography is a technique that evaluates the mechanical properties of tissues. Tendon pathology alters mechanical properties, and ultrasound elastography may be of value in improving the diagnostic capability of conventional ultrasound. Ultrasound elastography is based on the principle that tissue displacement in response to external compression produces strain within the tissue,⁵⁰ with *strain* defined as the change in length (displacement) of a tissue relative to its original length in response to the applied force. Stiffer tissues have lower strain values, while softer tissues have higher strain values. A visual strain map overlaid on the conventional brightness-mode (B-mode) image provides a visual representation of the relative stiffness of tissues (FIGURE 8).^{25,26,66,91}

Ooi et al⁶⁶ imaged 120 patients with Achilles tendinopathy and 120 sex- and age-matched controls. The authors found that combining findings from B-mode ultrasound and ultrasound elastography improved diagnostic sensitivity (0.96), specificity (0.95), and accuracy (0.98), with better clinical correlation ($\kappa = 0.9$, $P < .001$) when compared to B-mode and

color Doppler ultrasound (sensitivity, 0.67; specificity, 0.94; accuracy, 0.83).⁶⁶ Adding ultrasound elastography to conventional ultrasound may improve the association with clinical symptoms. Sonoelastography has previously been used to monitor the Achilles tendon postrupture⁹¹ and to investigate tissue displacement patterns under varying loading conditions,⁸⁷ and has been compared to histological specimens.⁵¹ Future studies are needed to investigate its potential role and applications in management and prevention of tendinopathy.

Can Imaging Predict the Onset of Pain or Clinical Outcome?

A feature and criticism of the use of imaging in individuals with tendinopathy is the poor correlation with the presence of pain and pain severity. Abnormal imaging has been reported in various tendons in as many as 59% of asymptomatic individuals.^{8,14,34,37,41,48,52} This reflects the complex nature, and our limited understanding, of tendon pain. Tendon pain is not solely driven by local tissue changes, yet there is likely to be an interaction between the local tissue and the peripheral and central nervous system.⁷⁷

Despite the poor relationship between pathological changes and pain, local tissue changes and the use of imaging in visualizing these changes may be important as a prognostic tool. Fredberg et al³⁵ followed 54 asymptomatic Danish elite soccer players for development of Achilles tendon pain over 12 months. The authors reported that players with substantial imaging changes (thickening and hypoechoic region greater than 2 mm in the transverse planes) at baseline had a 3-fold increase in the relative risk of developing symptoms (95% confidence interval [CI]: 1.6, 4.9). Similarly, Malliaras and Cook⁵⁶ reported that abnormal ultrasound imaging of the patellar tendon increased the relative risk of developing pain 15-fold in volleyball players (95% CI: 1.9, 111.4). Conversely, Giombini et al,³⁷ who investigated the Achilles, patellar, and quadriceps tendons in

37 asymptomatic elite fencers, reported that hypoechogenicity predicted future symptoms only in the patellar tendon, not the quadriceps or Achilles tendon.

Sonoelastography has been utilized to investigate the development of Achilles tendon pain in elite Australian football players. Structural and mechanical property changes of the Achilles tendon, such as intratendinous delaminations, hypoechogenicity, and neovascularization, as well as soft tendon properties, were present in 52.4% of asymptomatic elite Australian football players (unpublished data from Ooi et al). Increased mid-Achilles tendon thickness and cross-sectional area, intratendinous delaminations, and soft tendon texture were significant predictors for future symptoms. This suggests that conventional ultrasound supplemented with ultrasound elastography may identify Australian football players at risk of developing Achilles tendon injuries.

Structural disorganization observed on imaging should be considered as part of the risk factor profile for tendinopathy, similar to that of load, anthropometric factors, and genetics, rather than solely as a diagnostic feature. There is a significant association between polymorphisms within the gene that encodes type V collagen, COL5A1, and the presence of Achilles tendon pain.⁸³ Collins¹¹ states that gene variances are not predictive, but rather increase the risk of and susceptibility to developing the injury, similar to the increased risk of developing lung cancer in those with a history of smoking. Men who have smoked cigarettes for up to 20 years have an odds ratio of 7.4 (95% CI: 5.5, 9.8) for developing lung cancer.⁷⁰ Based on previous cross-sectional studies, abnormal Achilles tendons have odds ratios ranging from 3.9 (95% CI: 1.5, 10.2)⁴⁹ to 16.2 (95% CI: 6.0, 43.3)⁵² for the presence of tendon pain. While imaging and the presence of structural abnormalities should never be the sole or predominant tests in the prediction of future tendinopathy, local tissue structure may be a risk factor for the development of symptoms.

Monitoring of Tendon Structure: What Can We Expect From the Tendon?

To assess the efficacy of treatments, outcome measures of pain and function (Victorian Institute of Sport Assessment-Achilles [VISA-A] for the Achilles tendon⁷⁶), return to activity, and structure on imaging have been used. However, as mentioned earlier, assessment of tendon structure has been limited to subjective grading or measurements of tendon dimensions.

Recent studies that have semi-quantified aspects of tendon structure have provided information on how tendons respond structurally to various treatments. Shalabi et al⁸⁶ reported a significant decrease in Achilles tendon volume and intratendinous signal following a 3-month eccentric loading program. While improvements in tendon structure were observed, tendon volume and intratendinous signal did not return to normal. Similarly, long-term follow-up (mean of 4.2 years) of the same cohort reported no significant difference in tendon volume compared to baseline measures, despite improvements in pain and function.³⁶ Furthermore, previous research has found that Achilles tendon structure on UTC is no different after a 16-week eccentric loading program, despite improvements in the VISA-A score.²³ The findings of these studies suggest that improvements in the tendon are not necessary to facilitate clinical improvement after an eccentric exercise program. A systematic review by Drew et al³² reported that improvements in pain and function with eccentric exercise were not mediated by changes in tendon structure. In this context, while improvement in, or normalization of, tendon structure is a positive result, it is not necessary for improvement in pain and function, suggesting that the pathological tendon might have adapted to become, and remain, load tolerant.

While some interventions aim to regenerate and remodel structure within the tendon (eg, platelet-rich plasma, stem cells, autologous tenocyte implan-

tation), this may not be a necessary goal. Pathological Achilles and patellar tendons demonstrate an increased mean cross-sectional area of aligned fibrillar structure compared to structurally normal tendons.²⁸ Therefore, it appears that the pathological tendon maintains sufficient amounts of aligned fibrillar structure by increasing tendon dimensions (anteroposterior diameter and total mean cross-sectional area) in parallel with the mean cross-sectional area of disorganization (ie, the more disorganization, the bigger the tendon). The increase in tendon dimensions may be a mechanism by which the pathological tendon maintains sufficient mean cross-sectional area aligned fibrillar structure to still tolerate load. Interventions such as eccentric exercise may not be efficacious in remodeling the area of pathology; rather, these loading protocols may cause adaptation and increase the loading capacity of the surrounding aligned fibrillar structure.

In the context of previous research, stability in tendon structure accompanied by improvements in pain and function can be considered a positive outcome. Interestingly, rotator cuff tears that progressed were found to be related to an increased risk of symptom manifestation compared to those that remained stable over time.⁵⁵ Future research is needed to investigate whether tendons that remain stable, in terms of extent of pathology, have a better clinical outcome than those that worsen over time.

Future Directions for Research

Load is a critical factor in the development of tendinopathy, and numerous investigators are using imaging to improve our understanding of how tendons respond to load. Grigg et al³⁹ reported an acute response in the Achilles tendon, where anteroposterior diameter was reduced immediately after eccentric exercise and was restored after 24 hours. Ultrasound tissue characterization has been used to detect a short-term temporal response in the Achilles tendon⁷⁹ and

superficial digital flexor tendon of the horse,²⁹ in which a loss of aligned fibrillar structure was observed 48 hours after maximal load that returned to baseline at 3 to 4 days. This is consistent with other studies that have reported a short-term response in hydration level using off-resonance saturation MRI,⁹⁰ tendon volume and intratendinous signal on MRI,⁸⁴ and microvascular volume on real-time, harmonic, contrast-enhanced ultrasound⁷¹ in response to load. Of interest is that these studies reported an altered response in tendinopathic tendons.^{39,71,79}

These new imaging modalities may provide insight into how tendons respond to load. There is overwhelming evidence that structural disorganization predates the development of symptoms and tendon rupture.^{48,58} These new imaging modalities may help to define loading parameters that result in structural disorganization and to identify the point at which tendon load exceeds the tendon capacity.

Proposed Clinical Role of Imaging in Tendinopathy

In answering the question we posed in the title, imaging is not telling us the entire picture in tendinopathy. The role of imaging in the clinical setting may be somewhat limited, as it does not directly relate to symptoms. Imaging allows for the visualization of structure; it does not represent the entire clinical picture and should not be used as the sole diagnostic criterion in determining whether the clinical presentation is generated by the tendon. While imaging may not tell us the entire picture, just like pain on palpation gives us little information on muscular strength and endurance, it provides important information about structure. While not discussed as part of this review, imaging may be useful in differential diagnosis (eg, detection of an invaginated plantaris tendon,² paratenonitis), where treatment may need to be altered to address the specific condition.

As has been consistently stated throughout this narrative review, imag-

ing needs to be placed in the context of the overall clinical picture, and, despite the risk of potential bias, this may be enhanced by clinicians performing the imaging themselves (specifically ultrasound). However, caution is advised, with the potential for imaging in the clinician's hands to confuse the clinical picture and lead to poor outcomes due to technical insufficiencies. As stated above, ultrasound is highly user dependent, with specifically trained musculoskeletal radiologists able to produce high-quality images that may provide more clinically relevant information than those produced by clinicians with less experience in imaging. The converse to this discussion would be that in an attempt to improve the clinical utility of imaging, the radiologist may need to concern themselves further with the unique clinical presentation of tendinopathy. There is definitely scope for specialized musculoskeletal radiologists with a special interest in tendon imaging to take their own detailed history beyond the referral note. Whether it is the clinician having a role in imaging or the radiologist taking a detailed clinical history, there is a need for the sharing of skills and clear dialogue between the 2 fields to enhance the clinical utility of imaging.

In testing the efficacy of treatments or monitoring the improvement of clinical symptoms using imaging, a potential shift away from focusing on improving tendon structure may be needed. As clinical improvements have been shown not to be mediated by structural changes, stability in tendon structure may be a positive outcome in the clinical context of reduced pain and dysfunction. Currently, we are limited by the reliance of conventional imaging modalities on subjective interpretation. The development of new imaging techniques that utilize more quantifiable parameters, such as UTC or sonoelastography, will hopefully enhance our ability to diagnose, predict the development of symptoms, and monitor the efficacy of treatments. ●

REFERENCES

- Adams CR, Schoolfield JD, Burkhart SS. Accuracy of preoperative magnetic resonance imaging in predicting a subscapularis tendon tear based on arthroscopy. *Arthroscopy*. 2010;26:1427-1433. <http://dx.doi.org/10.1016/j.arthro.2010.02.028>
- Alfredson H. Midportion Achilles tendinosis and the plantaris tendon. *Br J Sports Med*. 2011;45:1023-1025. <http://dx.doi.org/10.1136/bjsports-2011-090217>
- Åström M, Gentz CF, Nilsson P, Rausing A, Sjöberg S, Westlin N. Imaging in chronic Achilles tendinopathy: a comparison of ultrasonography, magnetic resonance imaging and surgical findings in 27 histologically verified cases. *Skeletal Radiol*. 1996;25:615-620. <http://dx.doi.org/10.1007/s002560050146>
- Bashford GR, Tomsen N, Arya S, Burnfield JM, Kulig K. Tendinopathy discrimination by use of spatial frequency parameters in ultrasound B-mode images. *IEEE Trans Med Imaging*. 2008;27:608-615. <http://dx.doi.org/10.1109/TMI.2007.912389>
- Bleakney RR, White LM. Imaging of the Achilles tendon. *Foot Ankle Clin*. 2005;10:239-254. <http://dx.doi.org/10.1016/j.fcl.2005.01.006>
- Boesen MI, Boesen A, Koenig MJ, Bliddal H, Torp-Pedersen S. Ultrasonographic investigation of the Achilles tendon in elite badminton players using color Doppler. *Am J Sports Med*. 2006;34:2013-2021. <http://dx.doi.org/10.1177/0363546506290188>
- Bolton NR, Smith KE, Pilgram TK, Mueller MJ, Bae KT. Computed tomography to visualize and quantify the plantar aponeurosis and flexor hallucis longus tendon in the diabetic foot. *Clin Biomech (Bristol, Avon)*. 2005;20:540-546. <http://dx.doi.org/10.1016/j.clinbiomech.2004.12.007>
- Brasseur JL, Lucidarme O, Tardieu M, et al. Ultrasonographic rotator-cuff changes in veteran tennis players: the effect of hand dominance and comparison with clinical findings. *Eur Radiol*. 2004;14:857-864. <http://dx.doi.org/10.1007/s00330-003-2116-0>
- Calleja M, Connell DA. The Achilles tendon. *Semin Musculoskelet Radiol*. 2010;14:307-322. <http://dx.doi.org/10.1055/s-0030-1254520>
- Clegg PD, Strassburg S, Smith RK. Cell phenotypic variation in normal and damaged tendons. *Int J Exp Pathol*. 2007;88:227-235. <http://dx.doi.org/10.1111/j.1365-2613.2007.00549.x>
- Collins M. Genetic risk factors for soft-tissue injuries 101: a practical summary to help clinicians understand the role of genetics and 'personalised medicine'. *Br J Sports Med*. 2010;44:915-917. <http://dx.doi.org/10.1136/bjism.2009.058040>
- Comin J, Cook JL, Malliaras P, et al. The prevalence and clinical significance of sonographic tendon abnormalities in asymptomatic ballet dancers: a 24-month longitudinal study. *Br J Sports Med*. 2013;47:89-92. <http://dx.doi.org/10.1136/bjsports-2012-091303>
- Cook JL, Feller JA, Bonar SF, Khan KM. Abnormal tenocyte morphology is more prevalent than collagen disruption in asymptomatic athletes' patellar tendons. *J Orthop Res*. 2004;22:334-338. <http://dx.doi.org/10.1016/j.orthres.2003.08.005>
- Cook JL, Khan KM, Harcourt PR, et al. Patellar tendon ultrasonography in asymptomatic active athletes reveals hypoechoic regions: a study of 320 tendons. *Clin J Sport Med*. 1998;8:73-77. <http://dx.doi.org/10.1097/00042752-199804000-00001>
- Cook JL, Khan KM, Purdam C. Achilles tendinopathy. *Man Ther*. 2002;7:121-130. <http://dx.doi.org/10.1054/math.2002.0458>
- Cook JL, Kiss ZS, Ptasznik R, Malliaras P. Is vascularity more evident after exercise? Implications for tendon imaging. *AJR Am J Roentgenol*. 2005;185:1138-1140. <http://dx.doi.org/10.2214/AJR.04.1205>
- Cook JL, Malliaras P, De Luca J, Ptasznik R, Morris M. Vascularity and pain in the patellar tendon of adult jumping athletes: a 5 month longitudinal study. *Br J Sports Med*. 2005;39:458-461. <http://dx.doi.org/10.1136/bjism.2004.014530>
- Cook JL, Malliaras P, De Luca J, Ptasznik R, Morris ME, Goldie P. Neovascularization and pain in abnormal patellar tendons of active jumping athletes. *Clin J Sport Med*. 2004;14:296-299. <http://dx.doi.org/10.1097/00042752-200409000-00008>
- Cook JL, Purdam CR. Is tendon pathology a continuum? A pathology model to explain the clinical presentation of load-induced tendinopathy. *Br J Sports Med*. 2009;43:409-416. <http://dx.doi.org/10.1136/bjism.2008.051193>
- Corps AN, Robinson AH, Movin T, Costa ML, Hazleman BL, Riley GP. Increased expression of aggrecan and biglycan mRNA in Achilles tendinopathy. *Rheumatology (Oxford)*. 2006;45:291-294. <http://dx.doi.org/10.1093/rheumatology/kei152>
- de Jonge S, de Vos RJ, Weir A, et al. One-year follow-up of platelet-rich plasma treatment in chronic Achilles tendinopathy: a double-blind randomized placebo-controlled trial. *Am J Sports Med*. 2011;39:1623-1629. <http://dx.doi.org/10.1177/0363546511404877>
- De Jonge S, Warnars JL, De Vos RJ, et al. Relationship between neovascularization and clinical severity in Achilles tendinopathy in 556 paired measurements. *Scand J Med Sci Sports*. 2014;24:773-778. <http://dx.doi.org/10.1111/sms.12072>
- de Vos RJ, Heijboer MP, Weinans H, Verhaar JA, van Schie JT. Tendon structure's lack of relation to clinical outcome after eccentric exercises in chronic midportion Achilles tendinopathy. *J Sport Rehabil*. 2012;21:34-43.
- de Vos RJ, Weir A, Tol JL, Verhaar JA, Weinans H, van Schie HT. No effects of PRP on ultrasonographic tendon structure and neovascularisation

- in chronic midportion Achilles tendinopathy. *Br J Sports Med.* 2011;45:387-392. <http://dx.doi.org/10.1136/bjism.2010.076398>
25. De Zordo T, Chhem R, Smekal V, et al. Real-time sonoelastography: findings in patients with symptomatic Achilles tendons and comparison to healthy volunteers. *Ultraschall Med.* 2010;31:394-400. <http://dx.doi.org/10.1055/s-0028-1109809>
 26. De Zordo T, Fink C, Feuchtner GM, Smekal V, Reindl M, Klauser AS. Real-time sonoelastography findings in healthy Achilles tendons. *AJR Am J Roentgenol.* 2009;193:W134-W138. <http://dx.doi.org/10.2214/AJR.08.1843>
 27. Divani K, Chan O, Padhiar N, et al. Site of maximum neovascularisation correlates with the site of pain in recalcitrant mid-tendon Achilles tendinopathy. *Man Ther.* 2010;15:463-468. <http://dx.doi.org/10.1016/j.math.2010.03.011>
 28. Docking S, Cook J. Tendon size increases in parallel with tendon disorganisation: evidence of tendon remodelling to maintain adequate levels of aligned fibres [abstract]. *Br J Sports Med.* 2014;48:A20-A21. <http://dx.doi.org/10.1136/bjsports-2014-094114.31>
 29. Docking SI, Daffy J, van Schie HT, Cook JL. Tendon structure changes after maximal exercise in the Thoroughbred horse: use of ultrasound tissue characterisation to detect in vivo tendon response. *Vet J.* 2012;194:338-342. <http://dx.doi.org/10.1016/j.tvjl.2012.04.024>
 30. Docking SI, Rosengarten SD, Daffy J, Cook J. Structural integrity is decreased in both Achilles tendons in people with unilateral Achilles tendinopathy. *J Sci Med Sport.* 2015;18:383-387. <http://dx.doi.org/10.1016/j.jsams.2014.06.004>
 31. Dowling BA, Dart AJ, Hodgson DR, Smith RK. Superficial digital flexor tendonitis in the horse. *Equine Vet J.* 2000;32:369-378.
 32. Drew BT, Smith TO, Littlewood C, Sturrock B. Do structural changes (eg, collagen/matrix) explain the response to therapeutic exercises in tendinopathy: a systematic review. *Br J Sports Med.* 2014;48:966-972. <http://dx.doi.org/10.1136/bjsports-2012-091285>
 33. du Toit C, Stielor M, Saunders R, Bisset L, Vicenzino B. Diagnostic accuracy of power Doppler ultrasound in patients with chronic tennis elbow. *Br J Sports Med.* 2008;42:872-876. <http://dx.doi.org/10.1136/bjism.2007.043901>
 34. Fredberg U, Bolvig L. Significance of ultrasonographically detected asymptomatic tendinosis in the patellar and Achilles tendons of elite soccer players: a longitudinal study. *Am J Sports Med.* 2002;30:488-491.
 35. Fredberg U, Bolvig L, Andersen NT. Prophylactic training in asymptomatic soccer players with ultrasonographic abnormalities in Achilles and patellar tendons: the Danish Super League study. *Am J Sports Med.* 2008;36:451-460. <http://dx.doi.org/10.1177/0363546507310073>
 36. Gärdin A, Movin T, Svensson L, Shalabi A. The long-term clinical and MRI results following eccentric calf muscle training in chronic Achilles tendinosis. *Skeletal Radiol.* 2010;39:435-442. <http://dx.doi.org/10.1007/s00256-009-0798-3>
 37. Giombini A, Dragoni S, Di Cesare A, Di Cesare M, Del Buono A, Maffulli N. Asymptomatic Achilles, patellar, and quadriceps tendinopathy: a longitudinal clinical and ultrasonographic study in elite fencers. *Scand J Med Sci Sports.* 2013;23:311-316. <http://dx.doi.org/10.1111/j.1600-0838.2011.01400.x>
 38. Gisslén K, Alfredson H. Neovascularisation and pain in jumper's knee: a prospective clinical and sonographic study in elite junior volleyball players. *Br J Sports Med.* 2005;39:423-428. <http://dx.doi.org/10.1136/bjism.2004.013342>
 39. Grigg NL, Wearing SC, Smeathers JE. Achilles tendinopathy has an aberrant strain response to eccentric exercise. *Med Sci Sports Exerc.* 2012;44:12-17. <http://dx.doi.org/10.1249/MSS.0b013e318227fa8c>
 40. Grosse U, Syha R, Martirosian P, et al. Ultrashort echo time MR imaging with off-resonance saturation for characterization of pathologically altered Achilles tendons at 3 T. *Magn Reson Med.* 2013;70:184-192. <http://dx.doi.org/10.1002/mrm.24435>
 41. Hirschmüller A, Frey V, Konstantinidis L, et al. Prognostic value of Achilles tendon Doppler sonography in asymptomatic runners. *Med Sci Sports Exerc.* 2012;44:199-205. <http://dx.doi.org/10.1249/MSS.0b013e31822b7318>
 42. Hutchison AM, Evans R, Bodger O, et al. What is the best clinical test for Achilles tendinopathy? *Foot Ankle Surg.* 2013;19:112-117. <http://dx.doi.org/10.1016/j.fas.2012.12.006>
 43. Ingber DE. Control of capillary growth and differentiation by extracellular matrix. Use of a tensegrity (tensional integrity) mechanism for signal processing. *Chest.* 1991;99:34S-40S.
 44. Kainberger F, Mittermaier F, Seidl G, Parth E, Weinstabl R. Imaging of tendons—adaptation, degeneration, rupture. *Eur J Radiol.* 1997;25:209-222. [http://dx.doi.org/10.1016/S0720-048X\(97\)00058-2](http://dx.doi.org/10.1016/S0720-048X(97)00058-2)
 45. Kainberger FM, Engel A, Barton P, Huebsch P, Neuhold A, Salomonowitz E. Injury of the Achilles tendon: diagnosis with sonography. *AJR Am J Roentgenol.* 1990;155:1031-1036. <http://dx.doi.org/10.2214/ajr.155.5.2120931>
 46. Kålebo P, Allenmark C, Peterson L, Swärd L. Diagnostic value of ultrasonography in partial ruptures of the Achilles tendon. *Am J Sports Med.* 1992;20:378-381. <http://dx.doi.org/10.1177/036354659202000402>
 47. Khan KM, Cook JL, Bonar F, Harcourt P, Åstrom M. Histopathology of common tendinopathies. Update and implications for clinical management. *Sports Med.* 1999;27:393-408. <http://dx.doi.org/10.2165/00007256-199927060-00004>
 48. Khan KM, Cook JL, Kiss ZS, et al. Patellar tendon ultrasonography and jumper's knee in female basketball players: a longitudinal study. *Clin J Sport Med.* 1997;7:199-206.
 49. Khan KM, Forster BB, Robinson J, et al. Are ultrasound and magnetic resonance imaging of value in assessment of Achilles tendon disorders? A two year prospective study. *Br J Sports Med.* 2003;37:149-153. <http://dx.doi.org/10.1136/bjism.37.2.149>
 50. Klauser AS, Faschingbauer R, Jaschke WR. Is sonoelastography of value in assessing tendons? *Semin Musculoskelet Radiol.* 2010;14:323-333. <http://dx.doi.org/10.1055/s-0030-1254521>
 51. Klauser AS, Miyamoto H, Tamegger M, et al. Achilles tendon assessed with sonoelastography: histologic agreement. *Radiology.* 2013;267:837-842. <http://dx.doi.org/10.1148/radiol.13121936>
 52. Leung JL, Griffith JF. Sonography of chronic Achilles tendinopathy: a case-control study. *J Clin Ultrasound.* 2008;36:27-32. <http://dx.doi.org/10.1002/jcu.20388>
 53. Maffulli N, Khan KM, Puddu G. Overuse tendon conditions: time to change a confusing terminology. *Arthroscopy.* 1998;14:840-843. [http://dx.doi.org/10.1016/S0749-8063\(98\)70021-0](http://dx.doi.org/10.1016/S0749-8063(98)70021-0)
 54. Maffulli N, Longo UG, Franceschi F, Rabitti C, Denaro V. Movin and Bonar scores assess the same characteristics of tendon histology. *Clin Orthop Relat Res.* 2008;466:1605-1611. <http://dx.doi.org/10.1007/s11999-008-0261-0>
 55. Mall NA, Kim HM, Keener JD, et al. Symptomatic progression of asymptomatic rotator cuff tears: a prospective study of clinical and sonographic variables. *J Bone Joint Surg Am.* 2010;92:2623-2633. <http://dx.doi.org/10.2106/JBJS.I.00506>
 56. Malliaras P, Cook J. Patellar tendons with normal imaging and pain: change in imaging and pain status over a volleyball season. *Clin J Sport Med.* 2006;16:388-391. <http://dx.doi.org/10.1097/01.jsm.0000244603.75869.af>
 57. Malliaras P, Purdam C, Maffulli N, Cook J. Temporal sequence of greyscale ultrasound changes and their relationship with neovascularity and pain in the patellar tendon. *Br J Sports Med.* 2010;44:944-947. <http://dx.doi.org/10.1136/bjism.2008.054916>
 58. Malliaras P, Voss C, Garau G, Richards P, Maffulli N. Achilles tendon shape and echogenicity on ultrasound among active badminton players. *Scand J Med Sci Sports.* 2012;22:149-155. <http://dx.doi.org/10.1111/j.1600-0838.2010.01156.x>
 59. Mallinson PI, Stevens C, Reisinger C, Nicolaou S, Munk PL, Ouellette H. Achilles tendinopathy and partial tear diagnosis using dual-energy computed tomography collagen material decomposition application. *J Comput Assist Tomogr.* 2013;37:475-477. <http://dx.doi.org/10.1097/RCT.0b013e318287efa0>
 60. Meghoulaf A, Cloutier G, Crevier-Denoix N, de Guise JA. Tissue characterization of equine tendons with clinical B-scan images using a shock filter thinning algorithm. *IEEE Trans Med Imaging.* 2011;30:597-605. <http://dx.doi.org/10.1109/TMI.2010.2089636>
 61. Movin T, Kristoffersen-Wiberg M, Shalabi A, Gad A, Aspelin P, Rolf C. Intratendinous alterations

- as imaged by ultrasound and contrast medium-enhanced magnetic resonance in chronic achilodynia. *Foot Ankle Int*. 1998;19:311-317.
62. Nehrer S, Breitenseher M, Brodner W, et al. Clinical and sonographic evaluation of the risk of rupture in the Achilles tendon. *Arch Orthop Trauma Surg*. 1997;116:14-18.
63. Neuhold A, Stiskal M, Kainberger F, Schwaighofer B. Degenerative Achilles tendon disease: assessment by magnetic resonance and ultrasonography. *Eur J Radiol*. 1992;14:213-220. [http://dx.doi.org/10.1016/0720-048X\(92\)90090-V](http://dx.doi.org/10.1016/0720-048X(92)90090-V)
64. O'Brien M. Structure and metabolism of tendons. *Scand J Med Sci Sports*. 1997;7:55-61. <http://dx.doi.org/10.1111/j.1600-0838.1997.tb00119.x>
65. Öhberg L, Lorentzon R, Alfredson H. Neovascularisation in Achilles tendons with painful tendinosis but not in normal tendons: an ultrasonographic investigation. *Knee Surg Sports Traumatol Arthrosc*. 2001;9:233-238. <http://dx.doi.org/10.1007/s001670000189>
66. Ooi CC, Schneider M, Malliaras P, Chadwick M, Connell D. Diagnostic performance of son elastography in confirming clinically diagnosed Achilles tendinopathy: comparison with B-mode ultrasound and color Doppler imaging [poster]. 2014 Combined Scientific Meeting: Imaging and Radiation in Personalised Medicine; September 4-7, 2014; Melbourne, Australia.
67. Paavola M, Järvinen TA. Paratendinopathy. *Foot Ankle Clin*. 2005;10:279-292. <http://dx.doi.org/10.1016/j.fcl.2005.01.008>
68. Paavola M, Paakkala T, Kannus P, Järvinen M. Ultrasonography in the differential diagnosis of Achilles tendon injuries and related disorders. A comparison between pre-operative ultrasonography and surgical findings. *Acta Radiol*. 1998;39:612-619. <http://dx.doi.org/10.3109/02841859809175485>
69. Patterson-Kane JC, Rich T. Achilles tendon injuries in elite athletes: lessons in pathophysiology from their equine counterparts. *ILAR J*. 2014;55:86-99. <http://dx.doi.org/10.1093/ilar/ilu004>
70. Pesch B, Kendzia B, Gustavsson P, et al. Cigarette smoking and lung cancer—relative risk estimates for the major histological types from a pooled analysis of case-control studies. *Int J Cancer*. 2012;131:1210-1219. <http://dx.doi.org/10.1002/ijc.27339>
71. Pingel J, Harrison A, Simonsen L, Suetta C, Bülow J, Langberg H. The microvascular volume of the Achilles tendon is increased in patients with tendinopathy at rest and after a 1-hour treadmill run. *Am J Sports Med*. 2013;41:2400-2408. <http://dx.doi.org/10.1177/0363546513498988>
72. Puddu G, Ippolito E, Postacchini F. A classification of Achilles tendon disease. *Am J Sports Med*. 1976;4:145-150. <http://dx.doi.org/10.1177/036354657600400404>
73. Rasmussen OS. Sonography of tendons. *Scand J Med Sci Sports*. 2000;10:360-364. <http://dx.doi.org/10.1034/j.1600-0838.2000.010006360.x>
74. Reiman M, Burgi C, Strube E, et al. The utility of clinical measures for the diagnosis of Achilles tendon injuries: a systematic review with meta-analysis. *J Athl Train*. 2014;49:820-829. <http://dx.doi.org/10.4085/1062-6050-49.3.36>
75. Reinus WR, Shady KL, Mirowitz SA, Totty WG. MR diagnosis of rotator cuff tears of the shoulder: value of using T2-weighted fat-saturated images. *AJR Am J Roentgenol*. 1995;164:1451-1455. <http://dx.doi.org/10.2214/ajr.164.6.7754891>
76. Riley GP, Harrall RL, Constant CR, Chard MD, Cawston TE, Hazleman BL. Tendon degeneration and chronic shoulder pain: changes in the collagen composition of the human rotator cuff tendons in rotator cuff tendinitis. *Ann Rheum Dis*. 1994;53:359-366.
77. Rio E, Moseley L, Purdam C, et al. The pain of tendinopathy: physiological or pathophysiological? *Sports Med*. 2014;44:9-23. <http://dx.doi.org/10.1007/s40279-013-0096-z>
78. Robinson JM, Cook JL, Purdam C, et al. The VISA-A questionnaire: a valid and reliable index of the clinical severity of Achilles tendinopathy. *Br J Sports Med*. 2001;35:335-341. <http://dx.doi.org/10.1136/bjism.35.5.335>
79. Rosengarten SD, Cook JL, Bryant AL, Cordy JT, Daffy J, Docking SI. Australian football players' Achilles tendons respond to game loads within 2 days: an ultrasound tissue characterisation (UTC) study. *Br J Sports Med*. 2015;49:183-187. <http://dx.doi.org/10.1136/bjsports-2013-092713>
80. Samiric T, Parkinson J, Ilic MZ, Cook J, Feller JA, Handley CJ. Changes in the composition of the extracellular matrix in patellar tendinopathy. *Matrix Biol*. 2009;28:230-236. <http://dx.doi.org/10.1016/j.matbio.2009.04.001>
81. Scott A, Docking S, Vicenzino B, et al. Sports and exercise-related tendinopathies: a review of selected topical issues by participants of the second International Scientific Tendinopathy Symposium (ISTS) Vancouver 2012. *Br J Sports Med*. 2013;47:536-544. <http://dx.doi.org/10.1136/bjsports-2013-092329>
82. Screen HR, Shelton JC, Chhaya VH, Kayser MV, Bader DL, Lee DA. The influence of noncollagenous matrix components on the micromechanical environment of tendon fascicles. *Ann Biomed Eng*. 2005;33:1090-1099. <http://dx.doi.org/10.1007/s10439-005-5777-9>
83. September AV, Cook J, Handley CJ, van der Merwe L, Schwellnus MP, Collins M. Variants within the *COL5A1* gene are associated with Achilles tendinopathy in two populations. *Br J Sports Med*. 2009;43:357-365. <http://dx.doi.org/10.1136/bjism.2008.048793>
84. Shalabi A, Kristoffersen-Wiberg M, Aspelin P, Movin T. Immediate Achilles tendon response after strength training evaluated by MRI. *Med Sci Sports Exerc*. 2004;36:1841-1846.
85. Shalabi A, Kristoffersen-Wiberg M, Papadogiannakis N, Aspelin P, Movin T. Dynamic contrast-enhanced MR imaging and histopathology in chronic Achilles tendinosis. A longitudinal MR study of 15 patients. *Acta Radiol*. 2002;43:198-206. <http://dx.doi.org/10.1080/028418502127347781>
86. Shalabi A, Kristoffersen-Wiberg M, Svensson L, Aspelin P, Movin T. Eccentric training of the gastrocnemius-soleus complex in chronic Achilles tendinopathy results in decreased tendon volume and intratendinous signal as evaluated by MRI. *Am J Sports Med*. 2004;32:1286-1296. <http://dx.doi.org/10.1177/0363546504263148>
87. Slane LC, Thelen DG. Non-uniform displacements within the Achilles tendon observed during passive and eccentric loading. *J Biomech*. 2014;47:2831-2835. <http://dx.doi.org/10.1016/j.jbiomech.2014.07.032>
88. Smith TO, Back T, Toms AP, Hing CB. Diagnostic accuracy of ultrasound for rotator cuff tears in adults: a systematic review and meta-analysis. *Clin Radiol*. 2011;66:1036-1048. <http://dx.doi.org/10.1016/j.crad.2011.05.007>
89. Sundararajan PP, Wilde TS. Radiographic, clinical, and magnetic resonance imaging analysis of insertional Achilles tendinopathy. *J Foot Ankle Surg*. 2014;53:147-151. <http://dx.doi.org/10.1053/j.jfas.2013.12.009>
90. Syha R, Springer F, Grözinger G, et al. Short-term exercise-induced changes in hydration state of healthy Achilles tendons can be visualized by effects of off-resonant radiofrequency saturation in a three-dimensional ultrashort echo time MRI sequence applied at 3 Tesla. *J Magn Reson Imaging*. 2014;40:1400-1407. <http://dx.doi.org/10.1002/jmri.24488>
91. Tan S, Kudas S, Özcan AS, et al. Real-time sonoelastography of the Achilles tendon: pattern description in healthy subjects and patients with surgically repaired complete ruptures. *Skeletal Radiol*. 2012;41:1067-1072. <http://dx.doi.org/10.1007/s00256-011-1339-4>
92. Thorpe CT, Birch HL, Clegg PD, Screen HR. The role of the non-collagenous matrix in tendon function. *Int J Exp Pathol*. 2013;94:248-259. <http://dx.doi.org/10.1111/iep.12027>
93. van Schie HT, Bakker EM, Jonker AM, van Weeren PR. Computerized ultrasonographic tissue characterization of equine superficial digital flexor tendons by means of stability quantification of echo patterns in contiguous transverse ultrasonographic images. *Am J Vet Res*. 2003;64:366-375.
94. van Schie HT, Bakker EM, Jonker AM, van Weeren PR. Ultrasonographic tissue characterization of equine superficial digital flexor tendons by means of gray level statistics. *Am J Vet Res*. 2000;61:210-219.
95. van Schie HT, de Vos RJ, de Jonge S, et al. Ultrasonographic tissue characterization of human Achilles tendons: quantification of tendon structure through a novel non-invasive approach. *Br J Sports Med*. 2010;44:1153-1159. <http://dx.doi.org/10.1136/bjism.2009.061010>
96. Vlychou M, Dailiana Z, Fotiadou A, Papanagiotou M, Fezoulidis IV, Malizos K. Symptomatic partial rotator cuff tears: diagnostic performance of ultrasound and magnetic

[CLINICAL COMMENTARY]

resonance imaging with surgical correlation. *Acta Radiol.* 2009;50:101-105. <http://dx.doi.org/10.1080/02841850802600764>

97. Warden SJ, Kiss ZS, Malara FA, Ooi AB, Cook JL, Crossley KM. Comparative accuracy of magnetic resonance imaging and ultrasonography in confirming clinically diagnosed patellar tendinopathy. *Am J Sports Med.* 2007;35:427-436. <http://dx.doi.org/10.1177/0363546506294858>
98. Weinberg EP, Adams MJ, Hollenberg GM. Color

Doppler sonography of patellar tendinosis. *AJR Am J Roentgenol.* 1998;171:743-744. <http://dx.doi.org/10.2214/ajr.171.3.9725308>

99. Weinreb JH, Sheth C, Apostolakos J, et al. Tendon structure, disease, and imaging. *Muscles Ligaments Tendons J.* 2014;4:66-73.
100. Westacott DJ, Minns JI, Foguet P. The diagnostic accuracy of magnetic resonance imaging and ultrasonography in gluteal tendon tears - a systematic review. *Hip Int.* 2011;21:637-645.

101. Wijsekera NT, Calder JD, Lee JC. Imaging in the assessment and management of Achilles tendinopathy and paratendinitis. *Semin Musculoskelet Radiol.* 2011;15:89-100. <http://dx.doi.org/10.1055/s-0031-1271961>



MORE INFORMATION
WWW.JOSPT.ORG

EARN CEUs With JOSPT's Read for Credit Program

JOSPT's **Read for Credit (RFC)** program invites readers to study and analyze selected JOSPT articles and successfully complete online exams about them for continuing education credit. To participate in the program:

1. Go to www.jospt.org and click on **Read for Credit** in the top blue navigation bar that runs throughout the site.
2. Log in to read and study an article and to pay for the exam by credit card.
3. When ready, click **Take Exam** to answer the exam questions for that article.
4. Evaluate the RFC experience and receive a personalized certificate of continuing education credits.

The RFC program offers you 2 opportunities to pass the exam. You may review all of your answers—including your answers to the questions you missed. You receive **0.2 CEUs**, or 2 contact hours, for each exam passed.

JOSPT's website maintains a history of the exams you have taken and the credits and certificates you have been awarded in **My CEUs** and **Your Exam Activity**, located in the right rail of the Read for Credit page listing available exams.